

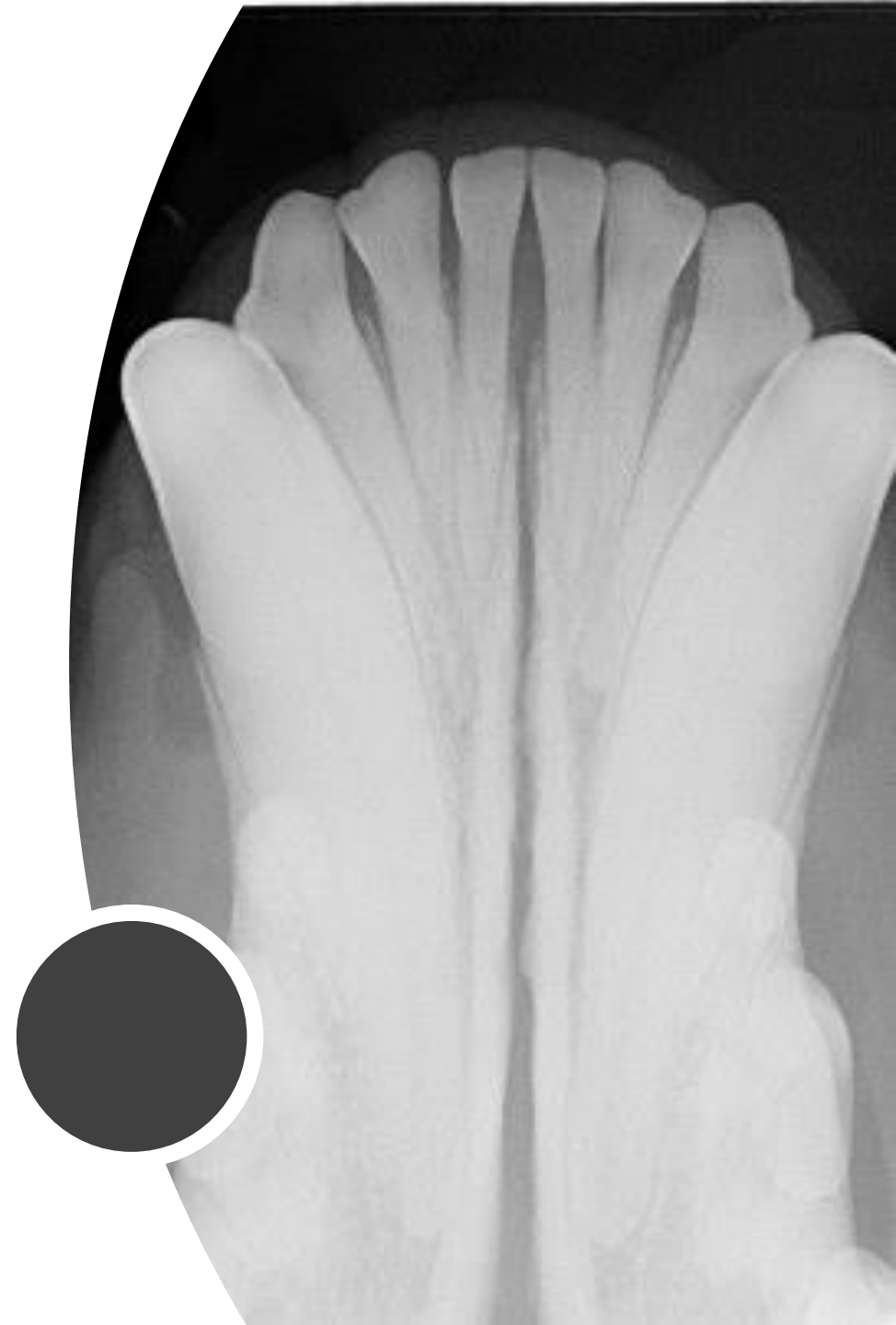Dental radiographic interpretation for the general practionner

By Josée Marcoux, DVM, DES dentistry
Evetmobile.dentisterie@gmail.com

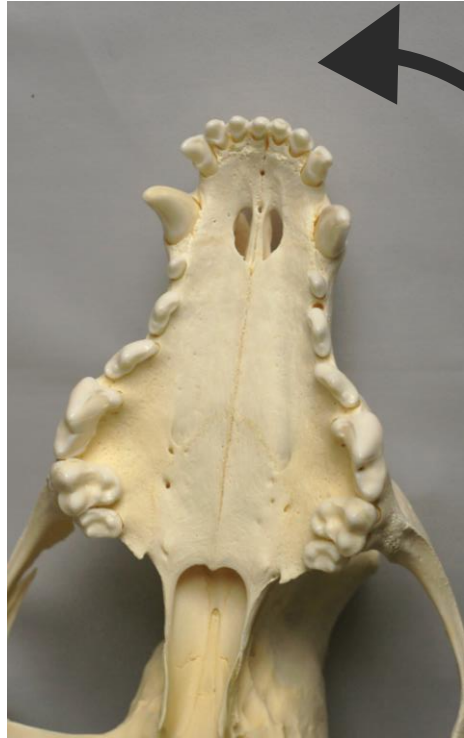Plan

1. Vocabulary
2. Normal anatomy
3. Endodontic disease
4. Periodontal disease
5. Tooth resorption
6. Cases



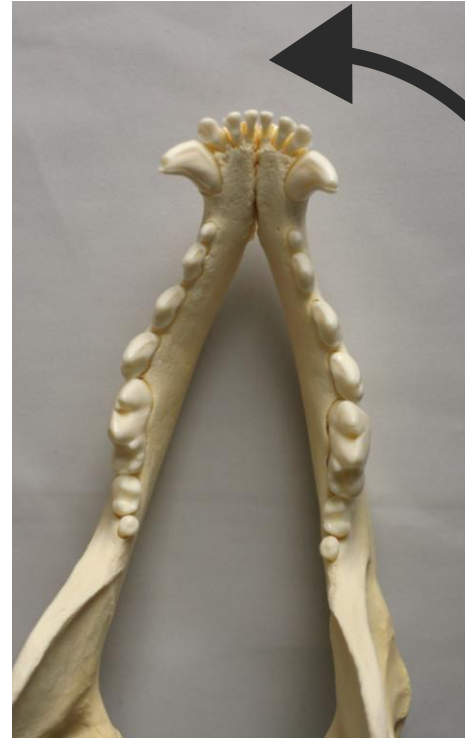Directionality

MESIAL



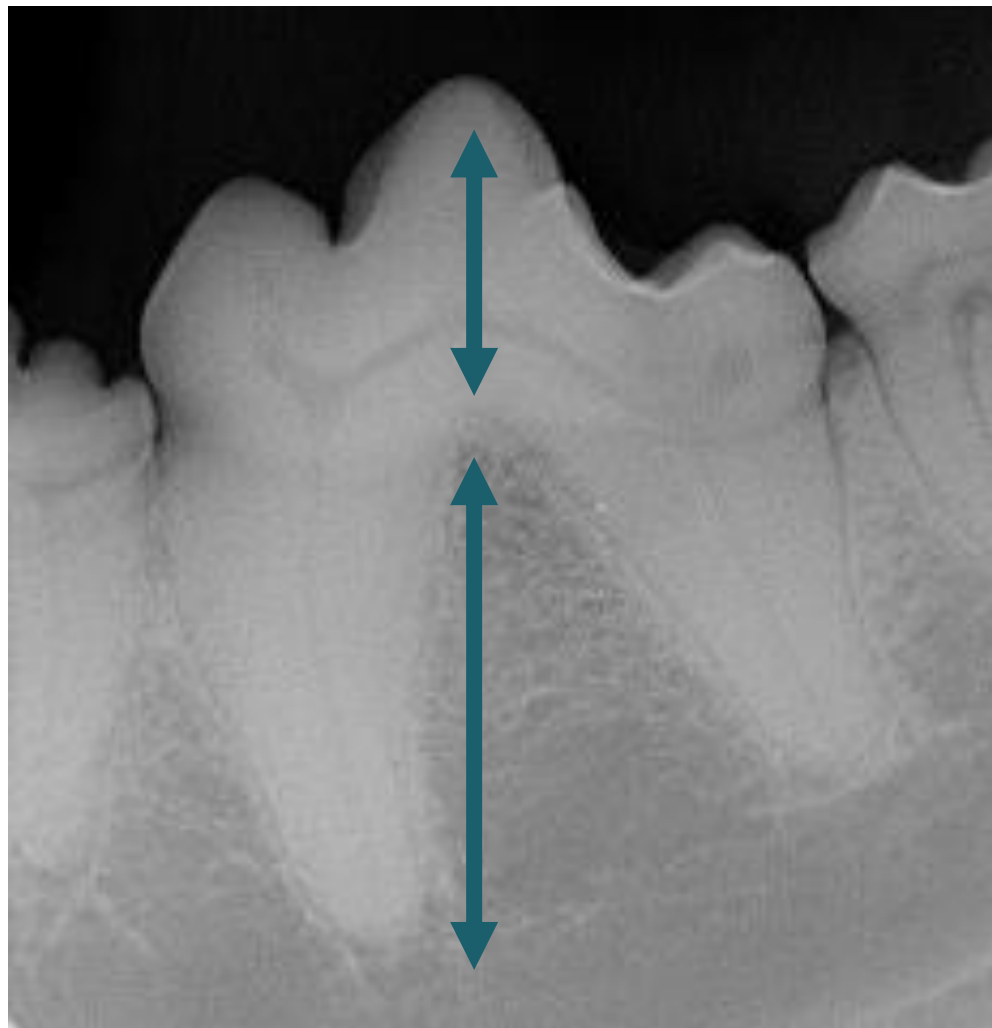DISTAL

MESIAL



DISTAL

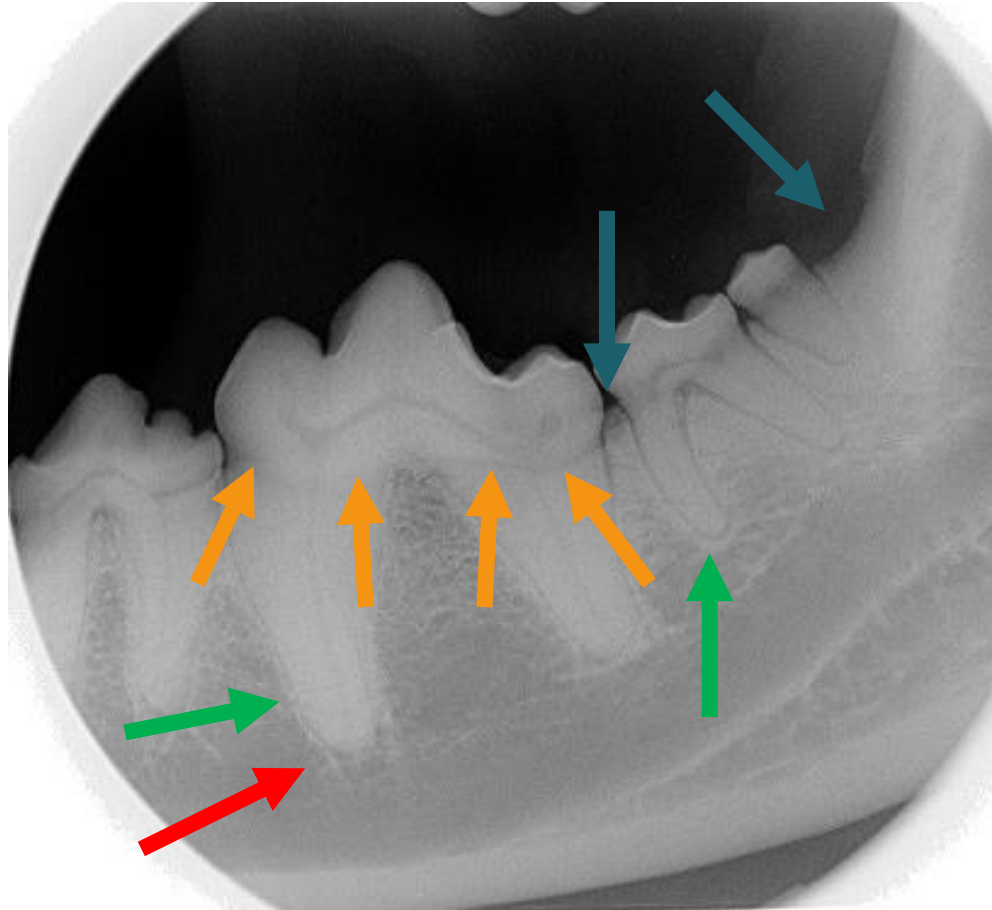
Directionality



OCCLUSAL
L
GINGIVAL
CORONAL

APICAL

Vocabulary



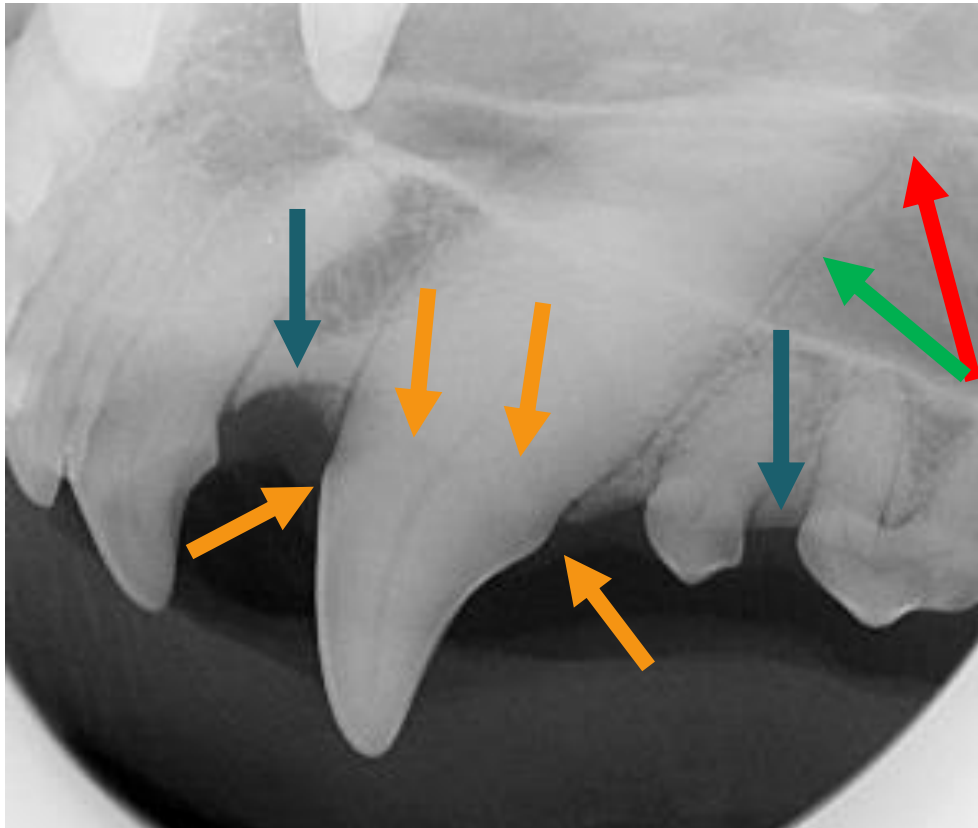
ALVEOLAR
MARGIN

CEMENTO
-ENAMEL
JUNCTION

LAMINA DURA

APEX

Vocabulary

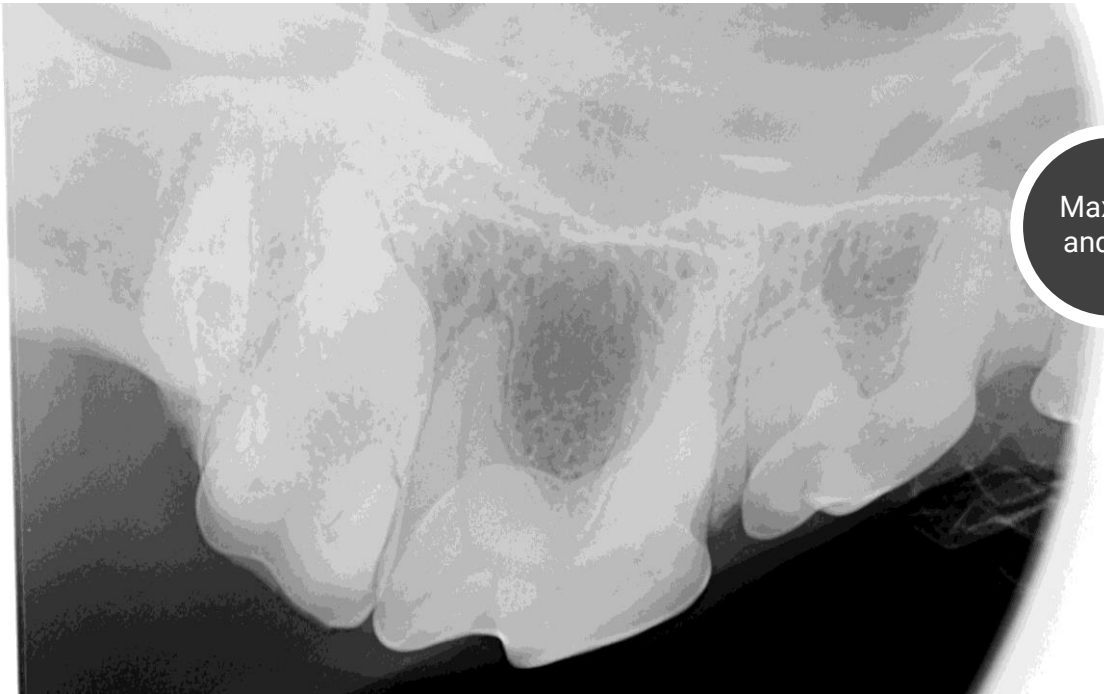


ALVEOLAR
MARGIN

CEMENTO
-ENAMEL
JUNCTION

LAMINA DURA

APEX



Max M1
and M2

Add Your Name :

lorem ipsum dolor sita amet hancon secasai teturasinasa
adipiscingesa nibuhase egetani han tincidunt velasa hani
eliqueta nibhasi elitases nusa adipis ascingesas nibuhase
adipiscingesa nibuhase egetani han tincidunt velasa hani
nliqueta nibhasi elitases nusa adipis ascingesas nibuhase
egetani tinciduntael velas il sedasas

Tricky teeth

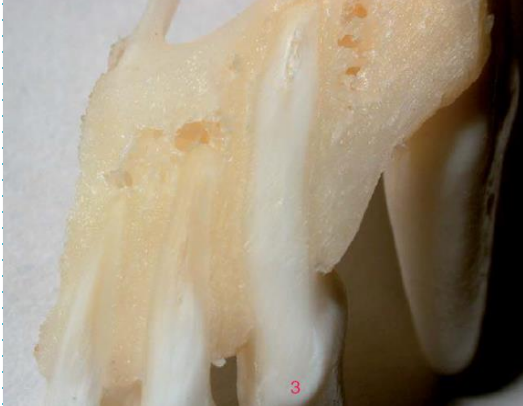- 79%

title here

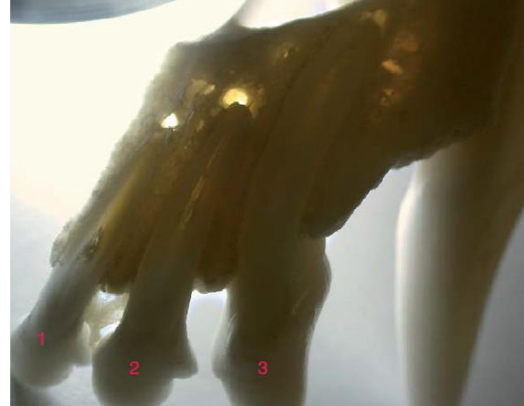
- 52%

title here

01. Add Your Name

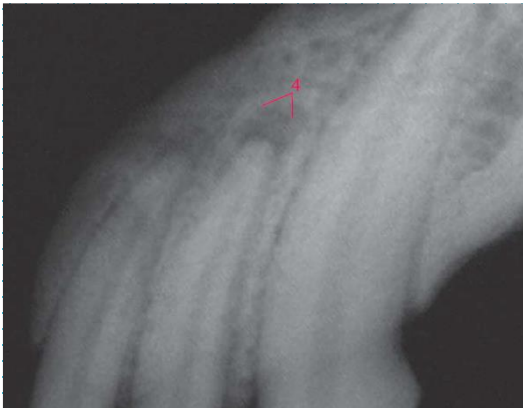


02. Add Your Name

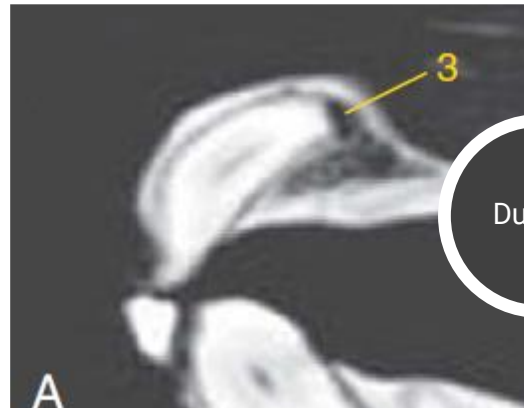


Chevron vs periapical lucency

- Chevron follows the profile of the root vs periapical lucency mushrooms out
- Continuity of the lamina dura
- Other side
- Context

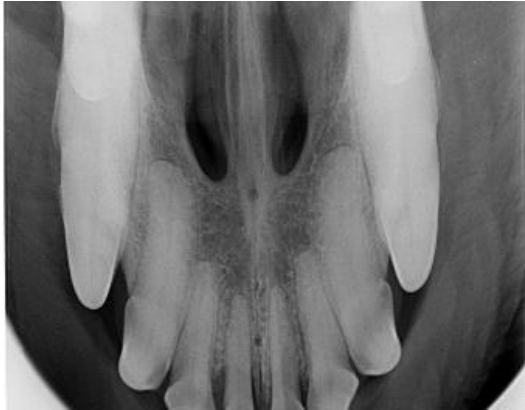


03. Add Your Name

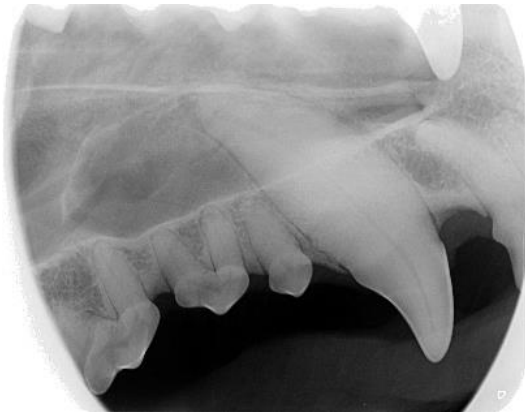
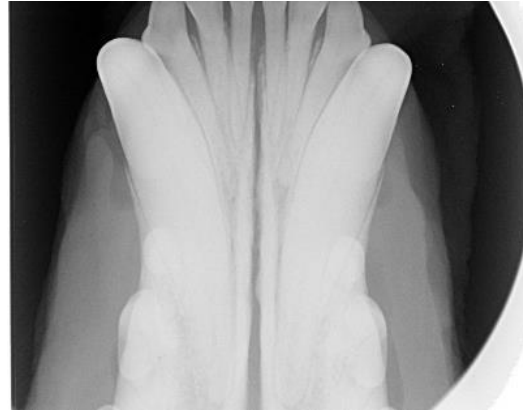
04. Add Your Name


01. Add Your Name



02. Add Your Name



03. Add Your Name



04. Add Your Name

Chevron vs periapical lucency


- Chevron follows the profile of the root vs periapical lucency mushrooms out
- Continuity of the lamina dura
- Other side
- Context

mples



My algorithm

1. Is my radiograph
diagnostic?






My algorithm

2. Anatomy

- Everyone present?
Extra?
- Shape
- Number of roots






My algorithm

3. Endodontic disease


- Integrity of the crown
- Size of the root canal
- Periapical lesion?



My algorithm

4. Periodontal disease

- Alveolar margin height in relation to the length from the cemento-enamel junction to the apex
- Stages of PD
 - 0 = perfect periodontium
 - 1 = gingivitis
 - 2 = 1-25% bone loss*
 - 3 = 26-50% bone loss
 - 4 = more than 50% bone loss






My algorithm

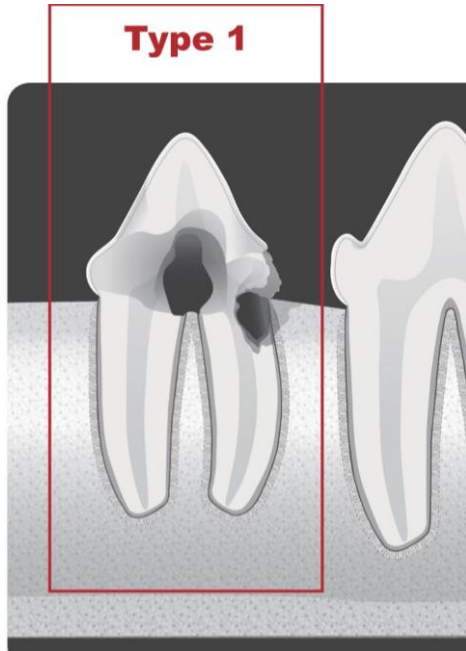
5. Resorption

- Dog
- Cat



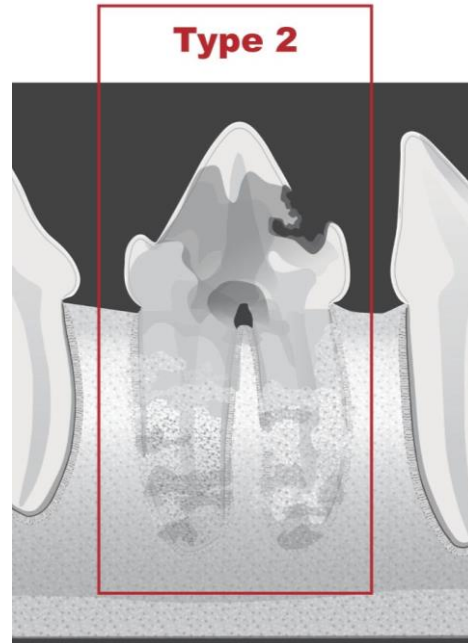
Tooth resorption in the cat

Avdc website



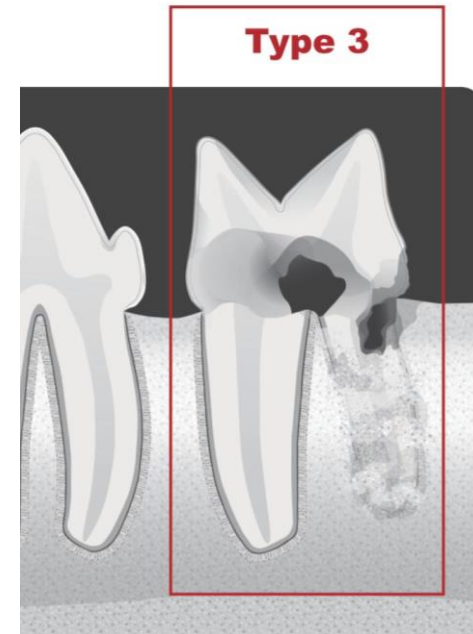
Type 1

lorem ipsum dolor consecas



Type 2

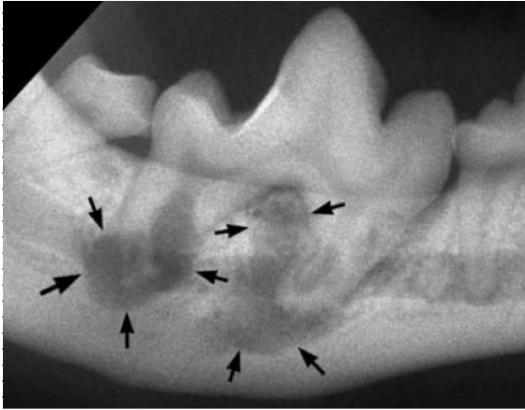lorem ipsum dolor consecas



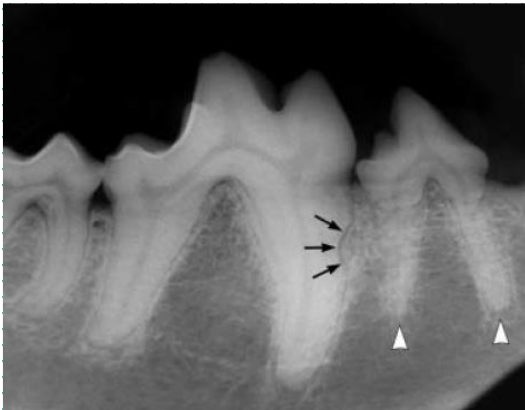
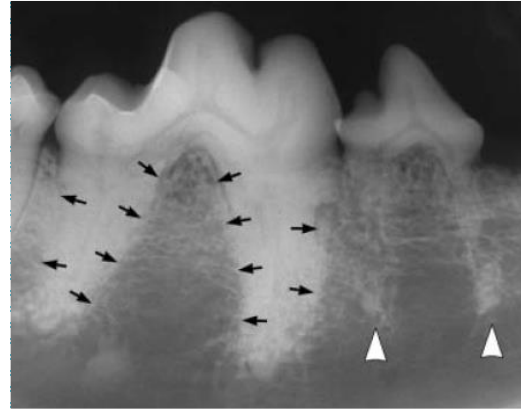
Type 3

lorem ipsum dolor consecas

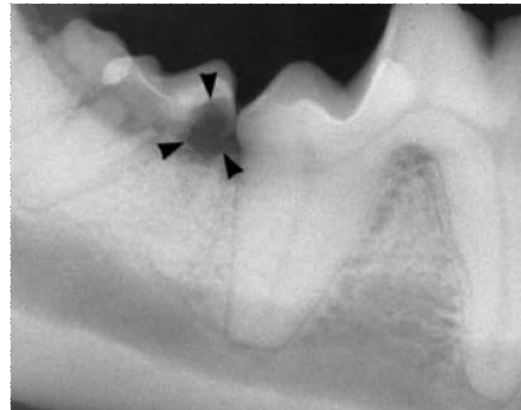
External inflammatory resorption



External surface resorption



External root surface resorption



External cervical root surface resorption

Types of resorption in the dog

- External inflammatory resorption
- External replacement resorption
- External root surface resorption
- External cervical root surface resorption

Clinical case 1

about us . contact us . more

lorem ipsum dolor sit amet consectetur adipiscing elit
nibhase eget justo sed gravida est sed onsec teturasanita elitasi
sed cursus mi ut sapien tincidunt velas aliqueta nisas adipiscing
elit sed cursus misani utasinau nasat bapienani

cursus mi ut sapien tincidunt velas aliqueta nibhase eseta justos
nibhase eget justo sed gravida est sedili teturasanit elitasi selit
sed cursus misani utasisa

Clinical case 1

about us . contact us . more

lorem ipsum dolor sit amet consectetur adipiscing elit
nibhase eget justo sed gravida est sed onsec teturasanita elitasi
sed cursus mi ut sapien tincidunt velas aliqueta nisas adipiscing
elit sed cursus misani utasinau nasat bapianani

cursus mi ut sapien tincidunt velas aliqueta nibhase eseta justos
nibhase eget justo sed gravida est sedili teturasanit elitasi selit
sed cursus misani utasisa

Clinical case 1

about us . contact us . more

lorem ipsum dolor sit amet consectetur adipiscing elit
nibhase eget justo sed gravida est sed onsec teturasanita elitasi
sed cursus mi ut sapien tincidunt velas aliqueta nisas adipiscing
elit sed cursus misani utasinau nasat bapianani

cursus mi ut sapien tincidunt velas aliqueta nibhase eseta justos
nibhase eget justo sed gravida est sedili teturasanit elitasi selit
sed cursus misani utasisa

Clinical case 1

about us . contact us . more

lorem ipsum dolor sit amet consectetur adipiscing elit nibhase eget justo sed gravida est sed onsec teturasanita elitasi sed cursus mi ut sapien tincidunt velas aliqueta nisas adipiscing elit sed cursus misani utasinau nasat bapianani

cursus mi ut sapien tincidunt velas aliqueta nibhase eseta justos nibhase eget justo sed gravida est sedili teturasanit elitasi selit sed cursus misani utasisa

Clinical case 1

about us . contact us . more

lorem ipsum dolor sit amet consectetur adipiscing elit
nibhase eget justo sed gravida est sed onsec teturasanita elitasi
sed cursus mi ut sapien tincidunt velas aliqueta nisas adipiscing
elit sed cursus misani utasinau nasat bapianani

cursus mi ut sapien tincidunt velas aliqueta nibhase eseta justos
nibhase eget justo sed gravida est sedili teturasanit elitasi selit
sed cursus misani utasisa

Clinical case 1

about us . contact us . more

lorem ipsum dolor sit amet consectetur adipiscing elit
nibhase eget justo sed gravida est sed onsec teturasanita elitasi
sed cursus mi ut sapien tincidunt velas aliqueta nisas adipiscing
elit sed cursus misani utasinau nasat bapianani

cursus mi ut sapien tincidunt velas aliqueta nibhase eseta justos
nibhase eget justo sed gravida est sedili teturasanit elitasi selit
sed cursus misani utasisa

Clinical case 1

about us . contact us . more

lorem ipsum dolor sit amet consectetur adipiscing elit
nibhase eget justo sed gravida est sed onsec teturasanita elitasi
sed cursus mi ut sapien tincidunt velas aliqueta nisas adipiscing
elit sed cursus misani utasinau nasat bapianani

cursus mi ut sapien tincidunt velas aliqueta nibhase eseta justos
nibhase eget justo sed gravida est sedili teturasanit elitasi selit
sed cursus misani utasisa

The background is a dark teal color with a faint, repeating pattern of interlocking gears. In the top-left and bottom-right corners, there are thin white lines that form a partial frame or corner indicator.

Thank You

evetmobile.dentisterie@gmail.com